

The ultrasound detection of chromosomal anomalies¹

Werther Adrian Clavelli, MD², Silvia Susana Romaris de Clavelli, MD², Philippe Jeanty, MD, PhD³

Adapted from “The Ultrasound Detection of Chromosomal Anomalies—A multimedia Lecture” by Philippe Jeanty. ISBN (0-9667878-0-3) available at www.prenataldiagnosis.com and www.TheFetus.net

Ultrasound findings during the first trimester

Although the majority of aneuploid fetuses are seen in the first trimester they usually present as failed pregnancy and impending miscarriages. Nether the less several observations should raise the suspicion in the first trimester of aneuploidy.

Nuchal edema

A small black space under the skin of the fetus behind the neck, is called a nuchal lucency between 10 and 14 weeks and a nuchal fold between 15 and 22 weeks. This is different from cystic hygroma in which a major amount of fluid accumulates under the skin behind the neck. A nuchal lucency is usually considered abnormal if it is greater than 2.5 mm between 10 and 14 weeks, (upper limits of 2 mm for embryos with a crown rump length of 35 mm, and 2.5 mm for embryos with a crown rump length of 85 mm)⁴. In practice, however it does not make much difference and 3 mm is a good cut off. The easiest way to obtain the measurement is to do a transvaginal examination, and try to get a view of the back of the neck of the baby.

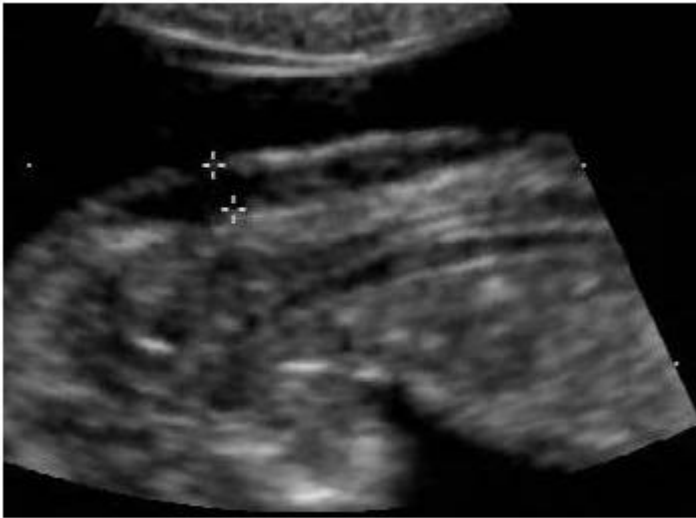


Figure 1 A small nuchal lucency. The measurement is obtained from one white line to the other.

The calipers should be placed on the white lines surrounding the nuchal lucency. The suspicion is that the nuchal lucency is due to over perfusion of the cephalic end of the fetus due to narrowing of the isthmus, which creates an increase of the size of the aorta over the ductus, and increases the perfusion of the cephalic end⁵. Further it appears that those embryos present with some early cardiac failure which is manifested by an abnormal ductus venosus tracing⁶. Overall about 30 percent of fetuses that have a nuchal lucency will have an aneuploidy, and the most common aneuploidies will be trisomy 21, trisomy 18, and monosomy X. Several studies have also demonstrated that the risk of aneuploidy increases with the thickness of the nuchal lucency^{7, 8, 9}. In fetuses in which the karyotype is normal in spite of the nuchal lucency, the nuchal lucency can also be a marker for non- chromosomal disorder in about four percent of

the time. This will include Noonan syndrome, cystic hygroma, hydrops, omphalocele, obstructive uropathy, genetic syndromes and many others are constantly being described. There is also a tendency for fetuses that have a thick nuchal lucency to have a poor outcome and decreased survival rate, compared to those that have a thin nuchal fold. Finally it is well known that nuchal lucency spontaneously regress and is rarely seen after 20 weeks.

Tight amnion

When the amnion is too close to the fetus like in these examples in which the gestational sac is predominantly occupied by the extra-amniotic coelom, and the amniotic cavity is tightly wrapped around the fetus, those fetuses are often at risk of trisomy 16 or triploidy.

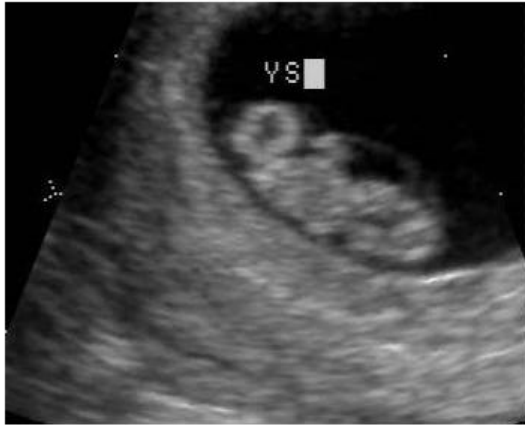


Figure 2: The amnion is very tightly apposed around this embryo. The embryo later miscarried and was identified as a trisomy 16.

2 vessel cord

The presence of a two-vessel cord can be a marker for aneuploidy. This is not typically searched for in the first trimester, but as fig 12 demonstrates the finding can be recognized in a 10 weeks fetus.

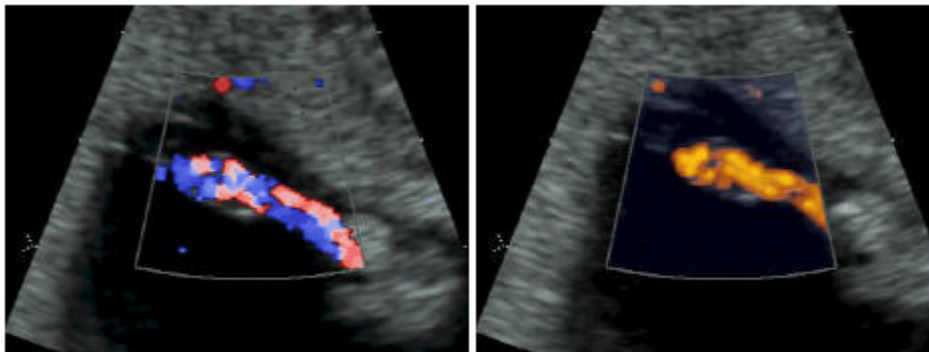


Figure 3: Color Doppler, and energy Doppler demonstrate a 2 vessel cord in a 10 week fetus.

One would look for a 2-vessel cord if the fetus has other findings such as a thick nuchal lucency for instance. 0.2 to 1 percent of pregnancies present with a two vessel cord. Among these, about 1 to 10 percent have an aneuploidy, including trisomy 18, 13, triploidy and monosomy X.

Yolk sac anomalies

Clifford Levi and Teddy Lyons have produced several papers in which they demonstrate that an irregular yolk sac or too large yolk sacs are factors that are predictors of pregnancies that will end up as miscarriage in the first trimester^{10, 11, 12}.

Major structural anomalies

The presence of certain major anomalies should also prompt a karyotype. Fig 15-17 represent three fetuses at nine and ten weeks. One appeared to have an omphalocele (greater than the normal physiological herniation of the guts¹³) and had trisomy 18, the other one had a large obstructed bladder and a small omphalocele and indeed had trisomy 13 and the last had alobar holoprosencephaly also within trisomy 18. Thus in the presence of major anomalies in the first trimester a karyotype is indicated.

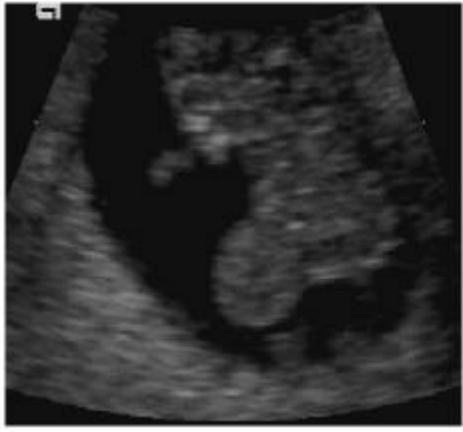

Figure 4: Omphalocele at 9 weeks. Trisomy 18

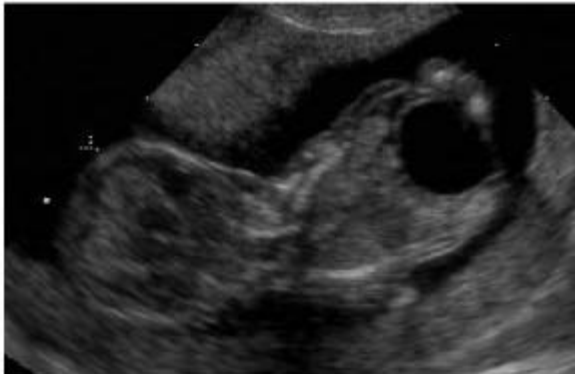


Figure 5: Posterior urethral valves in trisomy 13

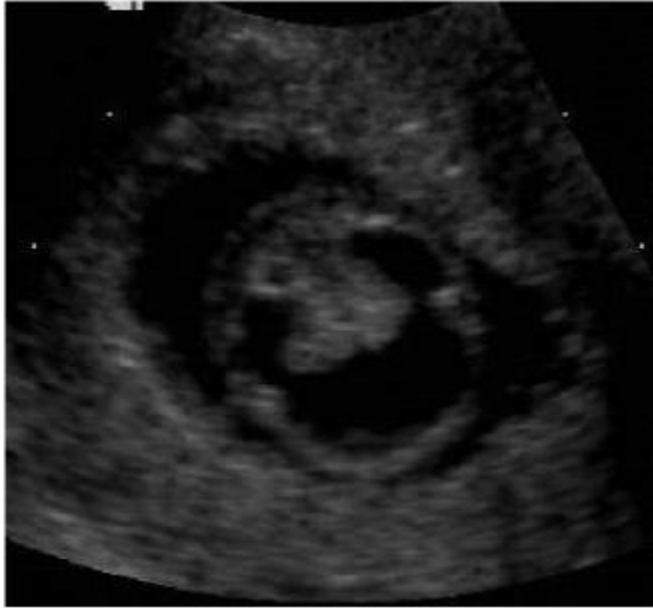

Figure 6: Alobar holoprosencephaly at 10 weeks. Trisomy 18.

Shapeless embryo

A shapeless embryo, is an embryo with no distinctive head and body at a time when these findings should be recognized. This can be a sign of various trisomies, usually very lethal trisomies such as trisomy 8, 16, and triploidy.

References

- ¹ Adapted from “The Ultrasound Detection of Chromosomal Anomalies—A multimedia Lecture” by Philippe Jeanty. ISBN (0-9667878-0-3) available at www.prenataldiagnosis.com and www.TheFetus.net
- ² Diagnostico Maipú, Buenos Aires, Argentina clavelli@arnet.com.ar
- ³ Women’s Health Alliance, Nashville, TN
- ⁴ Nicolaides KH, Brizot ML, Snijders RJ: Fetal nuchal translucency: ultrasound screening for fetal trisomy in the first trimester of pregnancy. *Br J Obstet Gynaecol* 1994 Sep;101(9):782-786
- ⁵ Hyett J, Moscoso G, Nicolaides K: Increased nuchal translucency in trisomy 21 fetuses: relationship to narrowing of the aortic isthmus. *Hum Reprod* 1995 Nov;10(11):3049-3051
- ⁶ Montenegro N, Matias A, Areias JC, Castedo S, Barros H: Increased fetal nuchal translucency: possible involvement of early cardiac failure. *Ultrasound Obstet Gynecol* 1997 Oct;10(4):265-268
- ⁷ Nicolaides KH, Brizot ML, Snijders RJ: Fetal nuchal translucency: ultrasound screening for fetal trisomy in the first trimester of pregnancy. *Br J Obstet Gynaecol* 1994 Sep;101(9):782-786
- ⁸ Pandya PP, Brizot ML, Kuhn P, Snijders RJ, Nicolaides KH: First-trimester fetal nuchal translucency thickness and risk for trisomies. *Obstet Gynecol* 1994 Sep;84(3):420-423
- ⁹ Pandya PP, Kondylis A, Hilbert L, Snijders RJ, Nicolaides KH: Chromosomal defects and outcome in 1015 fetuses with increased nuchal translucency *Ultrasound Obstet Gynecol* 1995 Jan;5(1):15-19.
- ¹⁰ Levi CS, Lyons EA, Lindsay DJ: Ultrasound in the first trimester of pregnancy. *Radiol Clin North Am* 1990 Jan;28(1):19-38
- ¹¹ Levi CS, Lyons EA, Lindsay DJ: Early diagnosis of nonviable pregnancy with endovaginal US. *Radiology* 1988 May;167(2):383-385

¹² Lyons EA, Levi CS: Ultrasound in the first trimester of pregnancy. *Radiol Clin North Am* 1982 Jun;20(2):259-270

¹³ van Zalen-Sprock RM, Vugt JM, van Geijn HP First-trimester sonography of physiological midgut herniation and early diagnosis of omphalocele. *Prenat Diagn* 1997 Jun;17(6):511-518