
The Genital Tract

Fetal Gender/ 301
Hydrometrocolpos/ 305
Ovarian Cysts/ 307

Fetal Gender

Embryology

Before the 8th menstrual week, the genitalia are in an ambiguous state. Normal female external genitalia are formed in the absence of testosterone. This hormone induces differentiation of the external genitalia in a male pattern. This process occurs between the 8th and 10th weeks (menstrual age).

Diagnosis

The most informative scanning planes for examination of fetal genitalia are coronal (Figs. 9-1, 9-2) and tangential sections (Figs. 9-3, 9-4).

A male fetus can be identified by visualization of a penis or scrotum as early as the 15th week. Testicular descent can also be diagnosed in utero. Birnholz has reported that descent occurs in 62 percent of

infants by the 30th week and in 93 percent of infants by the 32d week.¹ The incidence of cryptorchidism based on the pediatric literature varies according to gestational age and weight. The incidence is only 0.7 percent for those infants weighing above 3500 g, but as high as 17 percent in infants weighing between 2000 and 2500 g.⁴ A pitfall in identification of a penis is confusion with the umbilical cord or fetal fingers. An author has recently reported movement resembling fetal masturbation.^{4a}

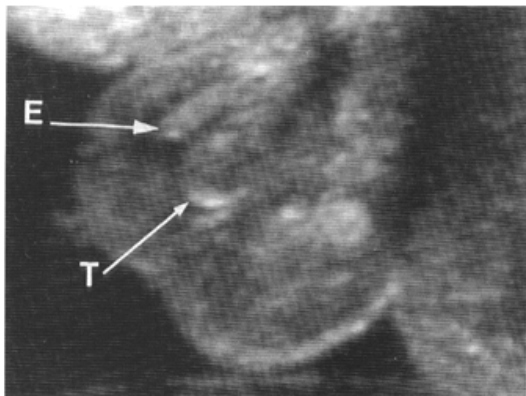


Figure 9-1. Coronal section of a third trimester male fetus. E, epididymis; T, testicle.

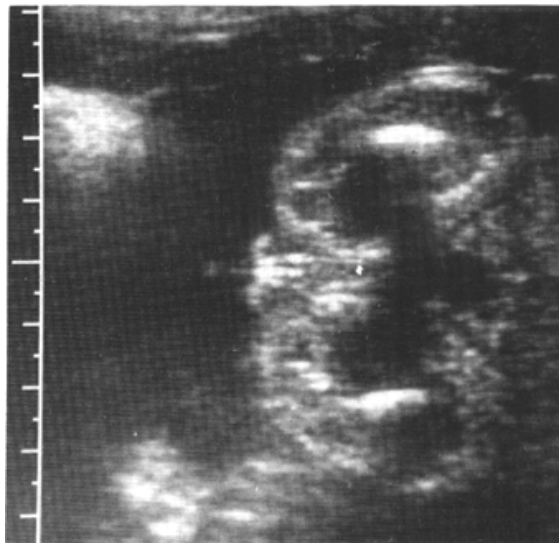

Figure 9-2. Coronal scan of a female fetus. Labia majora and minora are visible.

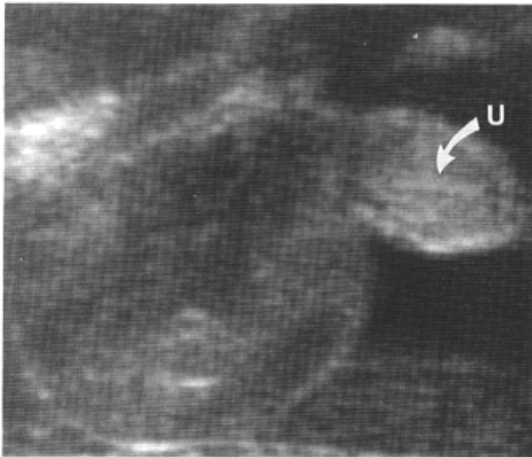


Figure 9-3. Male fetus scanned in a sagittal section. The scrotum and penis are visible. U, urethra.

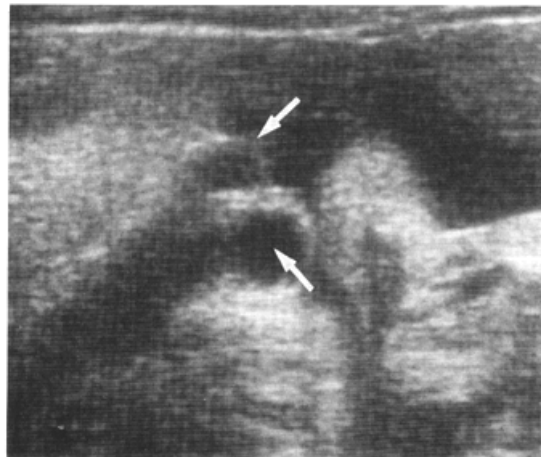


Figure 9-5. Edema of the labia majora. Arrows point to enlarged labia majora.

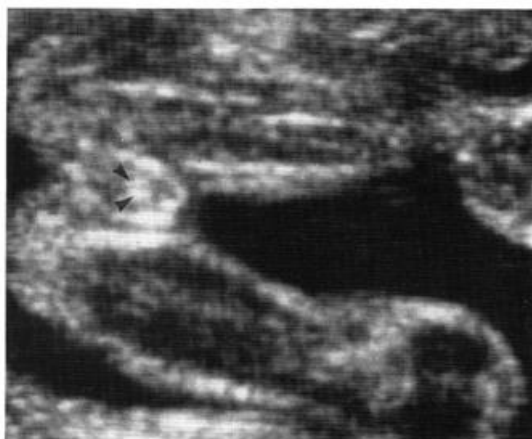


Figure 9-4. Scan of a female fetus. Arrowheads point to the labia minora.

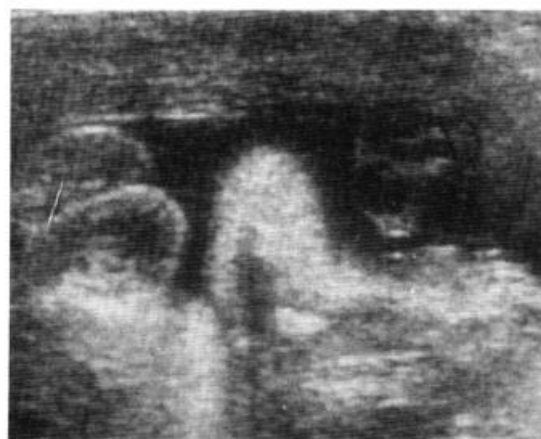

Figure 9-6. Edema of the labia majora. Note the similarity between the appearance of the swollen labia and the scrotum.

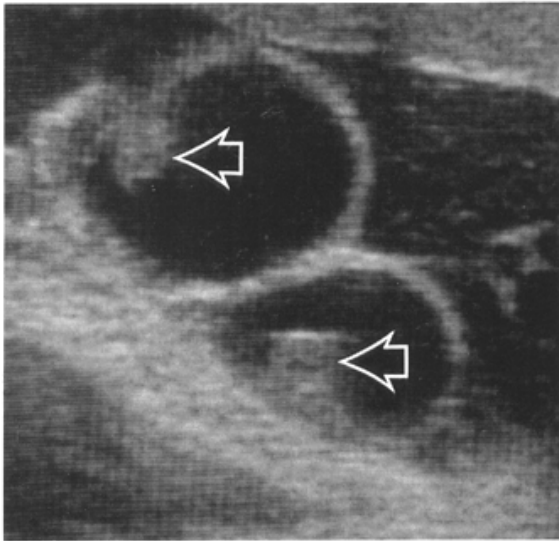


Figure 9-7. Hydrocele. Arrows point to the testes in the scrotal cavities.

Reliability of Prenatal Sex Determination. Published information about the accuracy of prenatal sex determination was reviewed recently by Elejalde et al. (Table 9-1).³ The accuracy is dependent on gestational age and operator experience. Stephens and Sherman are the only authors who claim 100 percent accuracy of sex diagnosis from the 16th to the 18th week.⁹ Elejalde et al. visualized fetal genitalia in 19 percent of infants between 15 and 18 weeks, with an error rate of 3.8 percent.³ Because of the finite error rate, we prefer to rely on chromosomal analysis

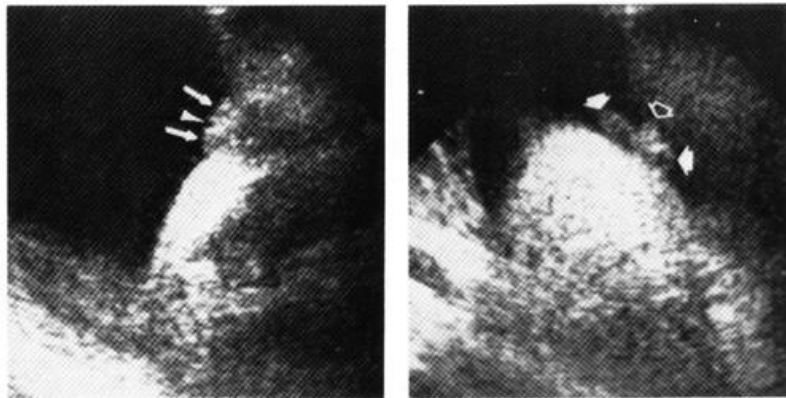
rather than ultrasound in assessing the risk of genetic disease in X-linked conditions.

Congenital Anomalies of External Genitalia

Hydrocele is the collection of fluid along the processus vaginalis. The processus vaginalis forms as an outpouching of peritoneum adjacent to the gubernaculum testis and progressively elongates through the inguinal canal. During the seventh month of gestation, it extends into the scrotum, followed by the descent of the epididymis and testes. The condition has been classified as noncommunicating and communicating. In the noncommunicating variety, fluid accumulates in the scrotum during the normal descent of the testes through the processus vaginalis. The communicating variety may be associated with an inguinal hernia. A prenatal diagnosis of hydrocele has been made by demonstrating the presence of fluid within the scrotum (Fig. 9-7).^{5,6} If the amount of fluid remains unchanged, the hydrocele is most likely of the noncommunicating variety. This condition requires no specific treatment and resolves spontaneously in most infants by 1 year of age. If the hydrocele enlarges throughout gestation, a communicating variety should be suspected. The neonatologist should look for an inguinal hernia.

Prenatal diagnosis of ambiguous genitalia by ultrasound has been reported by Cooper et al.² in a fetus at 34 weeks with extremely short limbs and ambiguous genitalia (Fig. 9-8). Chromosomal analysis showed a 46 XY karyotype with translocation from chromosome 9 to chromosome 3 (3q+ syndrome). Conditions that should be considered if ambiguous genitalia are diagnosed include adrenal hyperplasia, maternal androgen excess (due to ingestion in early pregnancy or to endogenous overproduction, such as an ovarian or adrenal tumor), and true hermaphroditism.

Figure 9-8. Ambiguous genitalia. Representative scan at 34 weeks showing ambiguous genitalia. Left sonogram shows a small midline cleft (*arrowhead*) separating two rounded structures (*arrows*), suggesting either labia majora or scrotal sac. A more cephalic scan (*right sonogram*) displays a small midline structure (*open arrow*) projecting between the two rounded structures (*closed arrows*). (Reproduced with permission from Cooper et al.: *J Ultrasound Med* 4.-433, 1985.)



The most common cause of ambiguous genitalia in chromosomally XX fetuses is congenital adrenal hyperplasia. The frequency of the disorder in the United States and Europe is between 1 in 5000 and 1 in 15,000.¹⁰ This common disorder is inherited as an autosomal recessive trait; its gene frequency is second only to that of cystic fibrosis. An early diagnosis is important because the condition may be life threatening during the newborn period due to electrolyte imbalance. The most common enzyme deficiency is 21-hydroxylase; 11-beta-hydroxylase deficiency also causes ambiguous genitalia. The metabolic abnormality results in deficient cortisol production, which increases the level of ACTH release with further steroid stimulation and an elevation of circulating androgens (see White et al.^{11,12}). A prenatal diagnosis of 21-hydroxylase deficiency has been made in a fetus at risk by measuring amniotic fluid levels of 17-hydroxy-progesterone and delta₄-androstenedione,¹⁰ and also by HLA typing of amniotic fluid cells. Although there are limitations to each method, a prenatal diagnosis is highly accurate when based on both techniques. Regrettably, amniocentesis is generally performed at 16 weeks; at this time, masculinization of affected females has already occurred. Diagnosis in the first trimester (chorionic villous sampling) may be possible in the future with the use of specific probes such as probes to the closely linked HLA class I and II genes.¹² Prenatal treatment with steroid administration to the mother from the 10th week may prevent ambiguous genitalia in female fetuses.¹² Testicular feminization syndrome has been diagnosed in an infant with an XY karyotype who had female genitalia.⁸

REFERENCES

1. Birnholz JC: Determination of fetal sex. *N Engl J Med* 309:942, 1983.
2. Cooper C, Mahony BS, Bowie JD: Prenatal ultrasound diagnosis of ambiguous genitalia. *J Ultrasound Med* 4:433, 1985.
3. Elejalde BR, de Elejalde MM, Heitman T: Visualization of the fetal genitalia by ultrasonography: A review of the literature and analysis of its accuracy and ethical implications. *J Ultrasound Med* 4:633, 1985.
4. Kogan S: Cryptorchidism. In: Kelalis PP, King LR, Belman AB (eds): *Clinical Pediatric Urology*, 2d ed. Philadelphia, Saunders, 1985, pp 864-887.
- 4a. Meizner I: Sonographic observation of in utero fetal masturbation." *J Ultrasound Med* 6:111, 1987.
5. Meizner I, Katz M, Zmora E, et al.: In utero diagnosis of congenital hydrocele. *J Clin Ultrasound* 11:449, 1983.
6. Miller EI, Thomas RH: Fetal hydrocele detected in utero by ultrasound. *Br J Radiol* 52:624, 1979.
7. Schotten A, Giese C: The "female echo": Prenatal determination of the female fetus by ultrasound. *Am J Obstet Gynecol* 138:463, 1980.
8. Stephens JD: Prenatal diagnosis of testicular feminisation. *Lancet* 2:1038, 1984.
9. Stephens JD, Sherman S: Determination of fetal sex by ultrasound. *N Engl J Med* 309:984, 1983.
10. Warsos SL, Larsen JW, Kent SG, et al.: Prenatal diagnosis of congenital adrenal hyperplasia. *Obstet Gynecol* 55:751, 1980.
11. White PC, New MI, Dupont B: Congenital adrenal hyperplasia (first of two parts). *N Engl J Med* 316:1519, 1987.
12. White PC, New MI, Dupont B: Congenital adrenal hyperplasia (second of two parts). *N Engl J Med* 316:1580, 1987.

Hydrometrocolpos

Definition

Hydrometrocolpos is a distention of the uterus (metro) and vagina (colpos) caused by obstruction to the drainage of genital secretions.

Incidence

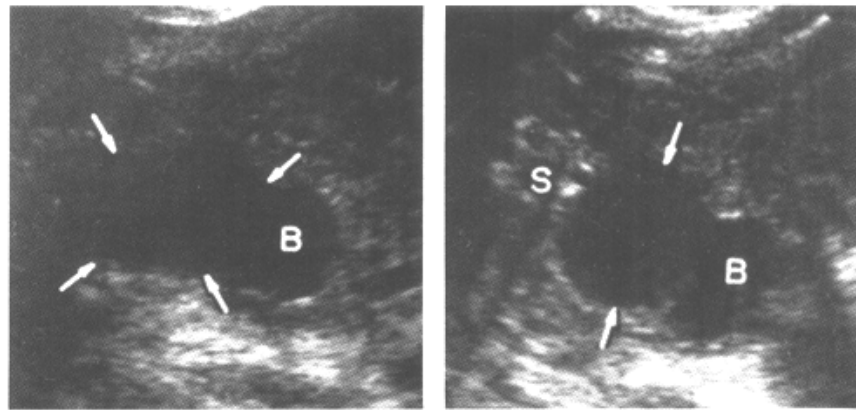
Less than 1 in 16,000 female births."

Etiology

Most cases of hydrometrocolpos are sporadic. Twenty-five cases of McKusick-Kaufman syndrome have

been reviewed by Robinow and Shaw.⁹ This syndrome consists of the association of hydrometrocolpos, polydactyly, and heart defects and is inherited with an autosomal recessive pattern. In this condition, hydrometrocolpos is due to either cervical or vaginal atresia and not to an imperforate hymen. Polydactyly and polysyndactyly are only postaxial and can be the only manifestation of the condition in males. Congenital heart disease may be a ventricular septal defect or a single atrium. Anorectal anomalies, such as rectovaginal fistulas, anal atresia, and vaginal and uterine duplication, occur in some cases.⁹

Figure 9-9. Sonogram of a hypo-echogenic, predominantly cystic, fetal pelvic mass (arrows). The left figure is a longitudinal scan, and the right is a transverse scan. B, bladder, S, spine. (Reproduced with permission from Davis et al: *J Ultrasound Med* 3:371, 1984.)



Pathology

Obstruction to the flow of secretions from the genital tract is due to a membrane that is frequently referred to as an "imperforate hymen." However, Dewhurst pointed out that the membrane does not correspond to the hymen, which can usually be seen externally to the obstructing membrane.⁴ Agnesis of the vagina or cervix can also be responsible for the obstruction.

The secretions that distend the uterus and vagina are produced by the uterine and cervical mucosas. These organs are under significant steroidal stimulation during fetal life.

The spectrum of hydrometrocolpos is broad, ranging from mild cases undetected until adolescence, when hematometrocolpos develops, to conditions occurring in the newborn as a huge pelviabdominal mass, with distention of the introitus and obstruction of the urinary tract. Sometimes, the con-

dition has been confused with an ovarian cyst. This diagnostic error has resulted in unnecessary hysterectomy.

Associated Anomalies

If the obstruction is due to a membrane, associated anomalies are absent. However, if the hydrometrocolpos is due to cervical or vaginal atresia, other anomalies are common and include imperforate anus, persistent urogenital sinus, unilateral renal agenesis or hypoplasia, polycystic kidneys, duplication of vagina and uterus, esophageal atresia, and sacral hypoplasia.^{5,7,8,11} Hydrometrocolpos has been described occasionally with Ellis-van Creveld syndrome.

Diagnosis

Hydrometrocolpos has been identified in utero.^{3,6,10} The condition occurred as a retrovesical mass with a

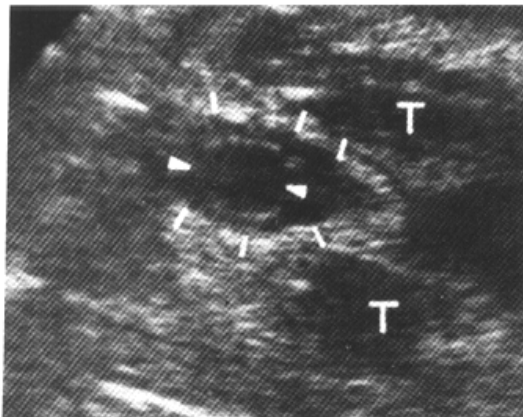


Figure 9-10. Transverse sonogram of the fetal perineum. Notice the hypoechoic cystic space (arrowheads) spreading the labia majora (lines). T, thigh. (Reproduced with permission from Davis et al: *J Ultrasound Med* 3:371, 1984.)

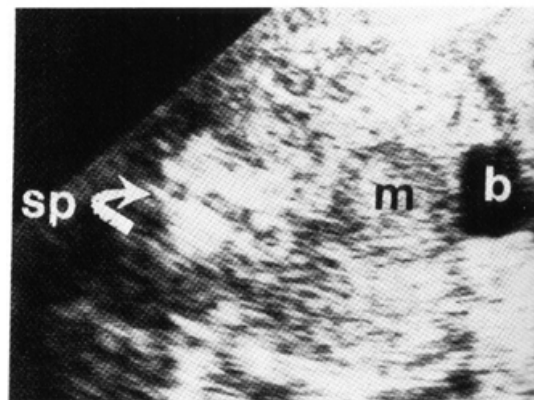


Figure 9-11. Transverse scan through the fetal lower abdomen. A solid mass (m) is seen behind the bladder (b). sp, spine. (Reproduced with permission from Hill, Hirsch: *J Ultrasound Med* 4 :323. 1985.)

sonographic appearance that in two patients was cystic^{3,10} and in one patient had midlevel echoes.⁶

An elegant prenatal diagnosis has been made by Davis et al.³ who found a hypoechogenic pelvic mass posterior to the bladder and anterior to the spine (Fig. 9-9). The mass extended cephalically into the fetal abdomen and caudally into the vagina. A coronal scan of the perineum showed spreading of the labia majora and protrusion of the mass (Fig. 9-10). Hydrometrocolpos is part of the differential diagnosis of any cystic intraabdominal mass in a female fetus (ovarian and mesenteric cysts, cystic tumors, anterior meningoceles). A precise diagnosis is difficult. When present, visualization of the perineal findings should be quite specific.

When hydrometrocolpos occurs as a noncystic mass (Fig. 9-11), differential diagnosis should include solid ovarian tumors, sacral tumors, such as chordoma or chondroma, and distended rectum.⁶ The solid sonographic image of some cases of fetal hydrometrocolpos is presumably due to the mucous nature of the secretion. To this extent, the term "hydrometrocolpos" would be a misnomer, and a more accurate term would be "mucometrocolpos."

The pelvic mass frequently causes urinary tract obstruction, which may appear as hydronephrosis.^{3,8,10} A rare complication described by Ceballos and Hicks is aseptic fibrous peritonitis after spillage of the genital secretions through the tubes into the peritoneal cavity.²

Prognosis

Hydrometrocolpos caused by a membrane can be treated easily by establishing vaginal patency. A more complex problem arises when the hydrometrocolpos is due to vaginal atresia or cervical atresia. An abdominal approach may be required. In the past, a mortality rate of up to 50 percent had been reported when infants underwent an exploratory laparotomy because of an undiagnosed hydrometrocolpos. There

are no data concerning the future fertility of infants with hydrometrocolpos.

Obstetrical Management

After viability, obstetrical management is not altered by this diagnosis. Serial scans are recommended to monitor the lesion.

REFERENCES

1. Akoun R, Bagard M: La maladie d' Ellis-van Creveld. *Algerie Med* 60:769,1956
2. Ceballos R, Hicks GM: Plastic peritonitis due to neonatal hydrometrocolpos: Radiologic and pathologic observations. *J Pediatr Surg* 5:63, 1970.
3. Davis GH, Wapner RJ, Kurtz AB, et al.: Antenatal diagnosis of hydrometrocolpos by ultrasound examination. *J Ultrasound Med* 3:371, 1984.
4. Dewhurst J: *Practical Pediatric and Adolescent Gynecology*. New York, Marcell Dekker, 1980, pp 67-74.
5. Graivier L: Hydrocolpos. *J Pediatr Surg* 4:563, 1969.
6. Hill SJ, Hirsch JH: Sonographic detection of fetal hydrometrocolpos. *J Ultrasound Med* 4:323, 1985.
7. Lide TN, Coker WG: Congenital hydrometrocolpos. Review of the literature and report of a case with uterus duplex and incompletely septate vagina. *Am J Obstet Gynecol* 64:1275, 1952.
8. Reed MH, Griscom NT: Hydrometrocolpos in infancy. *AJR* 118:1, 1973.
9. Robinow M, Shaw A: The McKusick-Kaufman syndrome: Recessively inherited vaginal atresia, hydrometrocolpos, uterovaginal duplications, anorectal anomalies, postaxial polydactyly and congenital heart disease. *J Pediatr* 94:776, 1979.
10. Russ PD, Zavitz WR, Pretorius DH, et al. Hydrometrocolpos, uterus didelphys, and septate vagina: An antenatal monographic diagnosis. *J Ultrasound Med* 5:211, 1986.
11. Westerhout FC, Hodgman JE, Anderson GV, et al.: Congenital hydrocolpos. *Am j Obstet Gynecol* 89:957, 1964.

Ovarian Cysts

Definition

An ovarian cyst is a fluid-filled ovarian tumor.

Incidence

Congenital ovarian cysts are rare. Less than 100 neonatal cases have been reported.

Etiology and Pathology

Unilateral cysts are more common than bilateral, and unilocular cysts are more common than septated

cysts. Size varies and ranges from small cysts to structures filling the entire abdomen.

The majority are benign cysts of germinal or graafian origin, such as simple cysts, theca-lutein cysts, and corpus luteum cysts. Granulosa cell tumors, benign cystic teratomas, and mesonephromas have also been reported in the newborn period, but they are rare compared to the cysts of germinal origin.^{2,7}

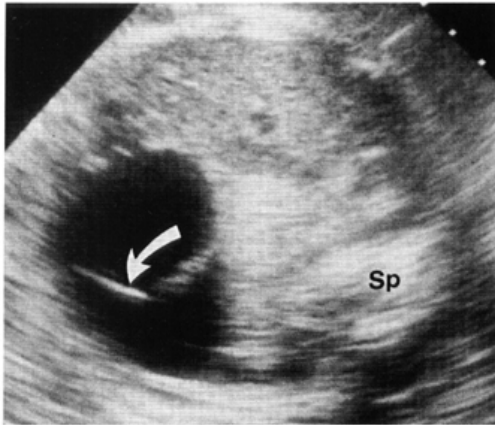


Figure 9-12. Transverse scan of the abdomen of a female fetus. A cystic lesion fills the anterior portion of the abdomen. A septum is indicated by the curved arrow. Sp, spine.

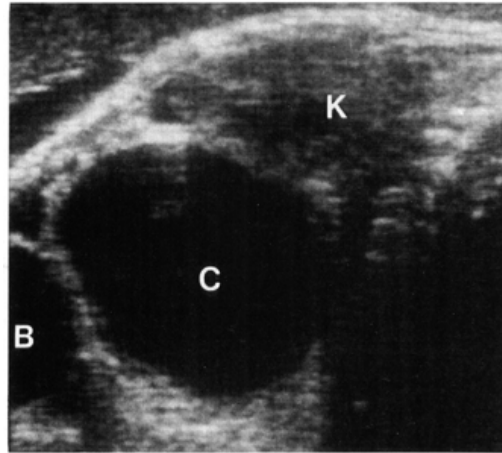


Figure 9-13. Oblique scan of a fetus with an ovarian cyst. The cystic lesion (C) is clearly seen. The bladder (B) is the hypoechoic image below the cyst. The kidney (K) is posterior to it.

Associated Anomalies

Associated congenital hypertrophic pyloric stenosis was reported in one patient. Hydrocephalus and absence of corpus callosum and of the pyramidal system were detected in another patient.¹³ Congenital hypothyroidism has been diagnosed in two patients.⁵

Diagnosis

An ovarian cyst should be suspected when a female fetus has a cystic intraabdominal mass, which is separated from the organs of the urinary and gastrointestinal tract (Figs. 9-12, 9-13).^{3,10,12-14,16,17} Layering echoes may be present inside the cyst.¹²

Differential diagnoses include urachal and mesenteric cysts, enteric duplication, duodenal atresia, and dilated bowel. Urachal cysts are single and anterior, extending from the bladder to the umbilicus. Mesenteric cysts and enteric cysts may be indistinguishable from ovarian cysts. The shape of enteric bowel duplication is generally tubular, but this is not enough for a differential diagnosis. Duodenal atresia has a typical double bubble appearance. A communication between the two bubbles may be shown, and polyhydramnios is the rule. Bowel obstructions show multiple dilated bowel loops and increased peristalsis. Polyhydramnios has been reported in 10 percent of cases of fetal ovarian cysts and probably results from gastrointestinal obstruction.¹⁴

Prognosis

The prognosis for ovarian cysts is good, since most are benign. In the newborn, large cysts may cause

ascites,¹ undergo torsion⁸ and infarction,⁹ lead to intestinal obstruction by membranous adhesions,⁴ rupture,¹⁵ or bleed.¹¹ Death may ensue because of massive hemoperitoneum. The frequency with which these accidents occur in utero is unknown.

Obstetrical Management

The detection of an intraabdominal hypoechogenic image compatible with an ovarian cyst does not alter standard obstetrical care. An exception to this is the extremely large cyst, which may cause dystocia or rupture during vaginal delivery. In one patient this accident led to neonatal death.⁷ If soft tissue dystocia is suspected, an elective cesarean section is a logical approach. An alternative would be to drain the cysts under ultrasound guidance. The theoretical risks of such an approach include spillage of an irritant (e.g., dermoid cysts) or a malignant tumor into the peritoneal cavity. The overwhelming majority of neonatal ovarian tumors are follicular or germinal in nature, and, therefore, the probability of this accident is low. Serial ultrasound examinations during pregnancy are recommended to monitor the growth of the cyst and possible complications. Torsion and bleeding of a pedunculated ovarian cyst can be suspected by the layering echoes inside the cyst¹² and by the transformation of a hypoechogenic mass into a hyper-echogenic one. Newborns with ovarian cysts should probably be evaluated for hypothyroidism.⁶

REFERENCES

1. Ahmed S: Neonatal and childhood ovarian cysts. *J Pediatr Surg* 6:702, 1971.
2. Carlson DH, Griscom NT: Ovarian cysts in the newborn. *AJR* 116:664, 1972.
3. Crade M, Gillooly L, Taylor KJM: In utero demonstration of an ovarian cyst mass by ultrasound. *J Clin Ultrasound* 8:251, 1980.
4. Dieter R.A Jr, Kindrachuk W, Muller RP: Neonatal intestinal obstruction due to torsion of an ovarian cyst. *J Fam Pract* 10:533, 1980.
5. Evers JL, Rolland R: Primary hypothyroidism and ovarian activity: Evidence for an overlap in the synthesis of pituitary glycoproteins. Case report. *Br J Obstet Gynecol* 88:195, 1981.
6. Jafri SZ, Bree RL, Silver TM, et al.: Fetal ovarian cysts: Sonographic detection and association with hypothyroidism. *Radiology* 150:809, 1984.
7. Jouppila P, Kirkinen P, Tuononen S: Ultrasonic detection of bilateral ovarian cysts in the fetus. *Eur J Obstet Gynecol Reprod Biol* 131:87, 1982.
8. Karrer FW, Swenson SA: Twisted ovarian cyst in a newborn infant: Report of a case. *Arch Surg* 83:921, 1961.
9. Marshall JR: Ovarian enlargements in the first year of life: Review of 45 cases. *Ann Surg* 161:372, 1965.
10. Mitsutake K, Abe I, Masumoto R, et al.: Prenatal diagnosis of fetal abdominal masses by real-time ultrasound. *Kurume Med J* 28:329, 1981.
11. Monson R, Rodgers BM, Nelson RM, et al.: Ruptured ovarian cyst in a newborn infant. *J Pediatr* 93:324, 1978.
12. Preziosi P, Fariello G, Maiorana A, et al.: Antenatal monographic diagnosis of complicated ovarian cysts. *J Clin Ultrasound* 14:196, 1986.
13. Sandler MA, Smith Sj, Pope SG, et al.: Prenatal diagnosis of septated ovarian cysts. *J Clin Ultrasound* 13:55, 1985.
14. Tabsh KMA: Antenatal monographic appearance of a fetal ovarian cyst. *J Ultrasound Med* 1:329, 1982.
15. Tietz KG, Davis JB: Ruptured ovarian cyst in a newborn infant. *J Pediatr* 51:564, 1957.
16. Touloukian RJ, Hobbins JC: Material ultrasonography in the antenatal diagnosis of surgically correctable fetal abnormalities. *J Pediatr Surg* 15:373, 1980.
17. Valenti C, Kassner EG, Yermakov V, et al.: Antenatal diagnosis of a fetal ovarian cyst. *Am J Obstet Gynecol* 123:216, 1975.